LIFE+VE

September 2023

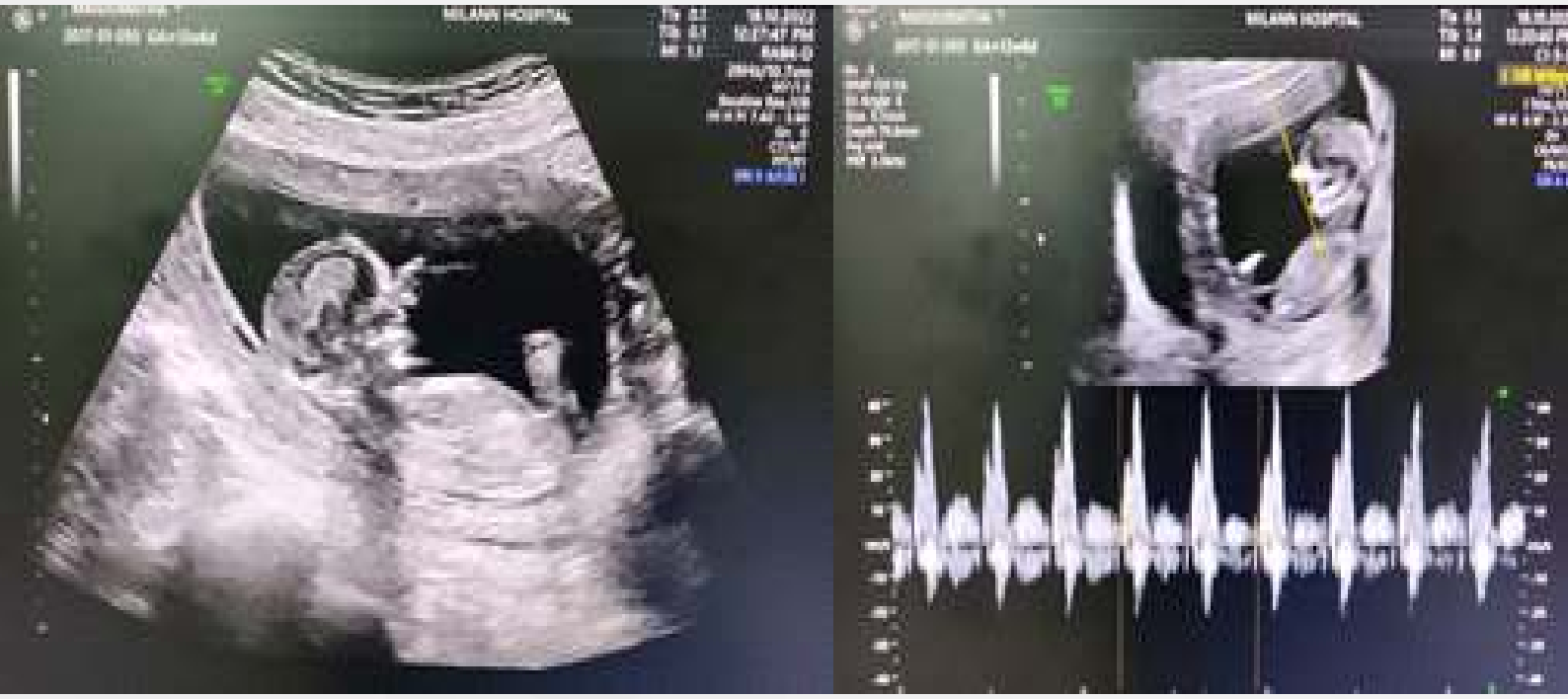

milann
The Fertility Specialists

A HCG Company
adding life to years

milann
The Fertility Specialists

Dr. Kamini A Rao

Founder & Chief Mentor
Milann Fertility

GREETINGS FROM MILANN!

The incidence of ectopic pregnancy after assisted reproductive technology is increased compared with natural conceptions as is the incidence of multiple high order pregnancies. We are pleased to bring to you our next issue of Life +ve with four interesting case reports pertaining to these issues following infertility treatment.

Our first case report on multiple ectopic pregnancies sheds light on the importance of appropriate individualized patient counselling regarding risks of recurrent ectopic pregnancy and its appropriate management in a case of tubal factor infertility.

The second article is a case of pregnancy of unknown location. It is important for the Clinician to follow up such cases carefully until a final diagnosis is established. In addition to TVUS, it is recommended to keep a constant watch on the Beta HCG levels and patient condition.

In our next article we present a case report of an early cervical ectopic pregnancy with a history of one previous caesarean section who was successfully managed with uterine artery embolization and Dilatation and Evacuation. Although cervical pregnancy is rare, increased number of cases are being reported because of risk factors like high cesarean section rate and increased assisted reproductive techniques for management of infertility.

The incidence of multifetal gestations has risen dramatically over the past few decades. Assisted reproductive techniques (ARTs) and the rising trend in advanced maternal age at first birth are the principal factors involved. We bring to you an interesting case of a quadruplet pregnancy following IUI which was reduced to twin and the complications faced by the patient during her antenatal journey.
We do hope you enjoy reading this issue as much as we have enjoyed bringing it to you.

Happy reading!

IVF for Tubal Disease- Is It All That Simple?

milann
The Fertility Specialists

DR. T SHILPA REDDY
Consultant, Reproductive Medicine
Milann, Kumara Park, Bangalore

DR. DOROTHY DESSA
Consultant, Reproductive Medicine
Milann, Kumara Park, Bangalore

Abstract

Ectopic pregnancy is an obstetrical emergency and the leading cause of maternal morbidity and mortality in the first trimester. Women with a history of prior ectopic pregnancy have an approximately eightfold increase in risk for a future ectopic pregnancy and there remains a gap in knowledge regarding prevention of recurrent ectopic pregnancies. Ectopic pregnancies are rare, but multiple recurrent ectopic pregnancies are much more rare and through this case we shed light on the importance of appropriate individualized patient counselling regarding risks of recurrent ectopic pregnancy and its appropriate management.

Introduction

Ectopic pregnancy is an obstetrical emergency and the leading cause of maternal morbidity and mortality in the first trimester . Ectopic pregnancies occur in 2% of all pregnancies, and women with a history of prior ectopic pregnancy have approximately an eightfold increase in risk for a future ectopic pregnancy. Rates of a third ectopic pregnancy have been shown to be significantly higher after expectant management of the second ectopic pregnancy compared to treatment with methotrexate or surgical intervention. In addition, rates of ectopic pregnancy following in vitro fertilization-embryo transfer (IVF-ET) are two- to three-fold greater compared to the general population. Classification of ectopic pregnancy varies based on location most common site being ampullary region of fallopian tube. Interstitial ectopic pregnancies are defined as products of conception in the interstitial area surrounded by a continuous rim of myometrium while cornual ectopic pregnancies occur as a result of implantation in the rudimentary horn of a unicornuate uterus, and stump ectopic pregnancies defined as implantation in the isthmic portion of the remnant tube after previous salpingectomy.

While risk factors for ectopic pregnancy have been studied, difficulty still exists in early identification of tubal stump ectopic pregnancies. We hereby report an interesting case of a woman with recurrent stump ectopic pregnancy following IVF and its successful management. This case discussion highlights the importance of having a high index of clinical suspicion initiating timely investigation so as to formulate appropriate treatment strategies for management of pregnancies following an ectopic pregnancy and preventing recurrent ectopic pregnancies.

Case Report

Mrs X, 31 years and Mr. Y, 33years, married for 4.5 years came to Milann seeking preconceptional care. She had regular menstrual cycles with normal duration and flow. Her past history was significant for a hysterolaparoscopy done 3 years ago for hydrosalpinx and a bilateral tubal clipping done . The presence of peritoneal tubercles was highly suspicious of Tuberculosis and the same was confirmed by a HPE .She completed a course of ATT .Upon evaluation she was found to have a normal ovarian reserve. Mr. Y had no significant past history and his semen analysis was normal . The couple were counselled for an IVF in view of tubal factor infertility.

IVF Cycle	Protocol	Total Dose	Days of Stimulation	Trigger	Oocytes & No of Mature Oocytes	Embryo Status	Fresh-ET
First	Antagonist	R-FSH-2700 HMG -300	11	Dual trigger	8 4 M2	3-8cga+ 1-8cgb	1-8cga+ 1-8cgb

In first IVF cycle (1-8 Cell GA & 1-8 Cell GB) was transferred (Fresh ET) and she failed to conceive. Subsequently an FET cycle with HRT protocol was planned and 2-8 Cell GA embryos were transferred. She conceived in the FET cycle.

Period of gestation	B-HCG	Scan (TVS)
4 weeks 3 days	639 mIU/ ml	-
5 weeks	1961 mIU/ ml	No intrauterine gestational sac seen. A gestational sac like structure seen at left adnexa. POD- clear. No probe tenderness
5 weeks 2 days	2855 mIU/ ml (45% rise in 48 hrs)	No intrauterine gestational sac seen. A gestational sac (0.23cm) with yolk sac noted in left adnexa suggestive of left tubal stump ectopic pregnancy. POD- clear.

The couple were counselled regarding the diagnosis of Ectopic Pregnancy and further management options were discussed. Medical management with single dose Methotrexate was done along with serial follow up with B-HCG estimation, which showed resolution.

In view of occurance of ectopic pregnancy despite tubal clipping, the couple were counselled about the role of laparoscopic salpingectomy as a more definitive procedure to prevent recurrence of future ectopic prior to the next IVF cycle. Having understood all the implications the couple still refused to undergo surgical management and chose to go for second cycle of IVF.

IVF Cycle	Protocol	Total Dose	Days of Stimulation	Trigger	Oocytes & No of Mature Oocytes	Embryo Status	Fresh-ET
Second	Antagonist	R-FSH-2025 HMG -675	9	Dual trigger	12-11 M2	9-8Cell GA	Fresh ET deferred in view of high E2 level (4200pg/ml)

Following second IVF cycle she underwent a FET (HRT protocol) with Blastocyst (2x 4AA)transfer, but failed to conceive.
In third FET (HRT Protocol)-3-8Cell GA were transferred and she conceived.

Period of Gestation	B-HCG	Scan (TVS)
4 weeks 3 days	361 mIU/ ml	-
4 weeks 6 days	548 mIU/ ml	-
5 weeks 3 days	1531 mIU/ ml	No intrauterine gestational sac seen. A small gestational sac with a small yolk sac noted in right adnexa suggestive of right stump ectopic pregnancy. POD- clear.

Since patient had recurrent stump ectopic pregnancy proceeding ahead with medical management was not a suitable option. Couple were thoroughly counselled regarding the need for operative laparoscopy and they agreed for the same .During laparoscopy intraoperatively dense adhesions were noted (Fig 1).Both the tubes were delinked from the uterus by cauterizing the cornual end .

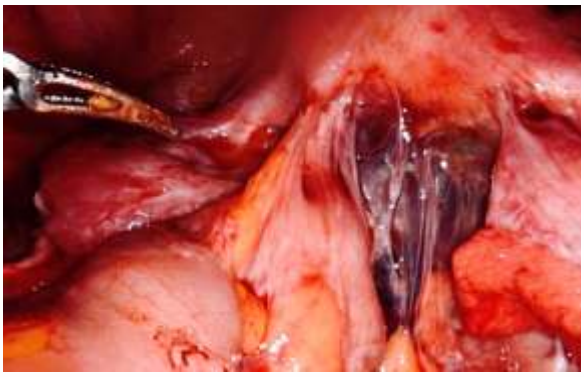

Fig 1 :Laparoscopy image of pelvis demonstrating dense adhesions

Subsequent to the laparoscopy patient underwent mild stimulation FET with Tamoxifen in which 2 blastocyst (4AA,3AA) were transferred and she conceived(Fig 2&3). Beta HCG 2 weeks post ET was 1496 mIU/ml. Scan showed intrauterine gestational sac corresponding to POG. She has been under periodic follow up with us and is currently 24 weeks of gestational age with no antenatal complications so far.

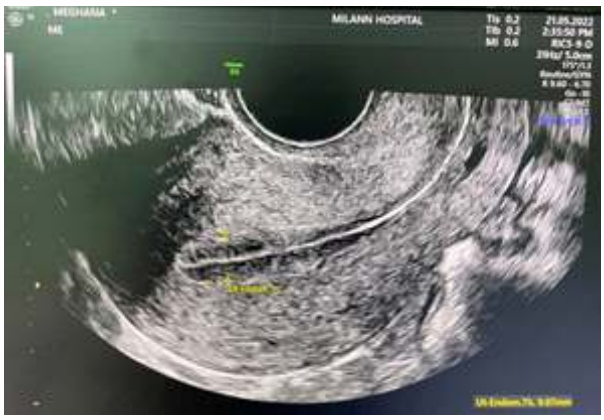

Fig2a: 2D Scan during Endometrial Preparation for FET

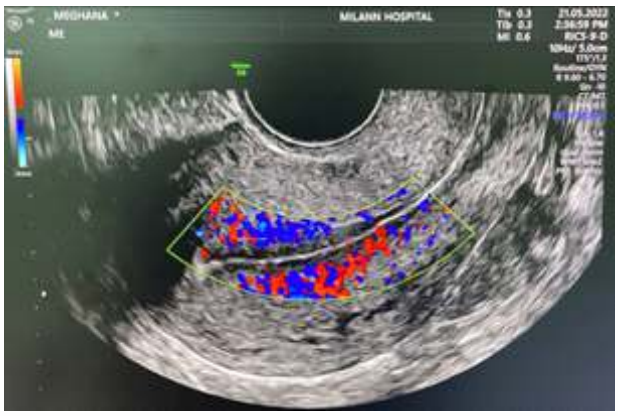

Fig2b: Colour Doppler study during Endometrial Preparation for FET

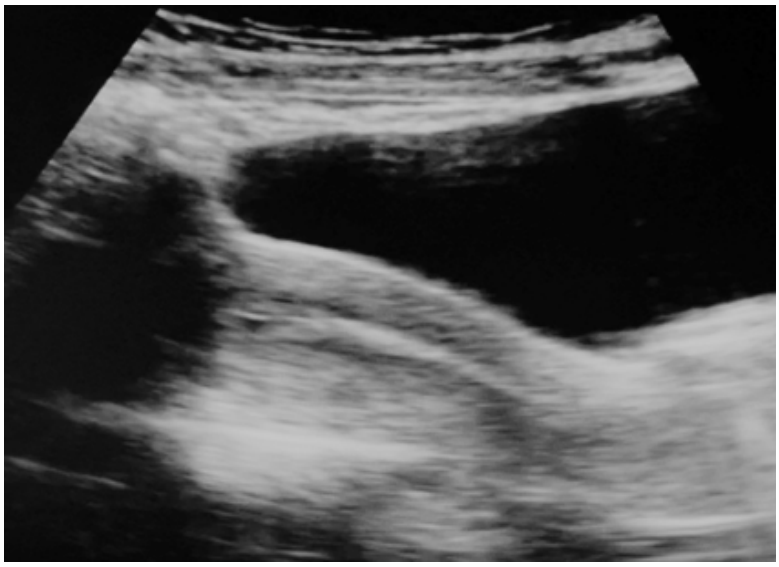

Fig3: Ultrasound Guided Embryo transfer

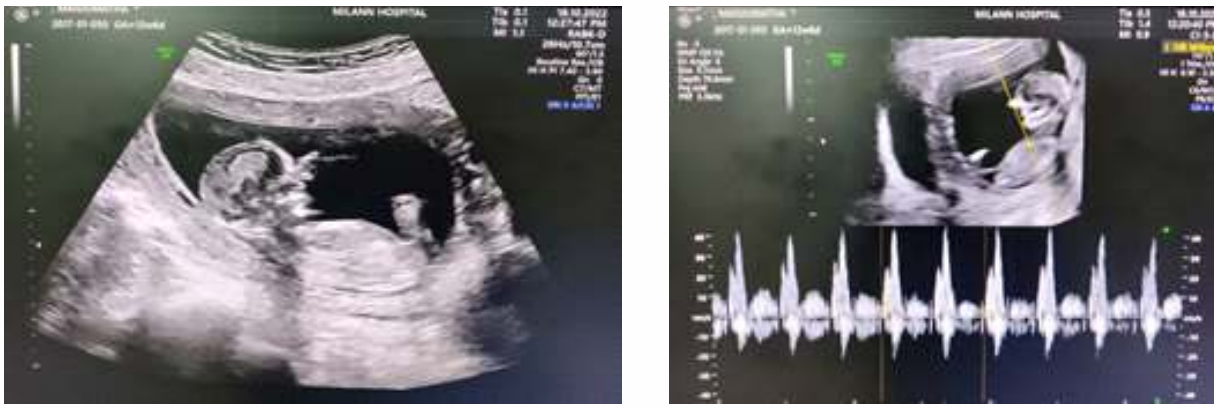

Fig 4: USG showing Single live intrauterine pregnancy corresponding to 12 weeks 6 days of gestation

Discussion

Ectopic pregnancy is a common cause of acute abdomen in obstetrics and gynecology, and it is also one of the important causes of maternal death. While ART meets people's fertility needs, it has a risk of ectopic pregnancy, which can easily increase the incidence of recurrent ectopic pregnancy.

The incidence of ectopic pregnancy is around 1-2%. Approximately 92% of ectopic pregnancies occur in the ampullary region of the fallopian tubes, 2.5% as interstitial/cornual ectopic pregnancies, while less-common forms include cervical, ovarian, and peritoneal. Ectopic pregnancy occurring in the remnant stump of the fallopian tube following salpingectomy is even less common. There have been isolated case reports in literature showing few cases of ectopic pregnancy in proximal or distal stump after total or partial salpingectomy or after adnexectomy. However, the exact incidence of ectopic pregnancy in the remnant stump following salpingectomy is not known currently. Takeda et al. reported an incidence of 1.16% in their department from January 1994 to August 2005.

A comprehensive literature search was done to find out the sonographic features which would clearly distinguish between an interstitial pregnancy, an angular pregnancy, pregnancy in isthmic remnant of the tube or cornual pregnancy. However, the ultrasound signs are subtle and confusing with no clear differentiating features amongst these. The use of high-resolution transvaginal sonography or 3D sonography can be of aid in obtaining the coronal scans of fundal region of the uterus thus giving more information of the uterine cornua. Laparoscopy and direct visualization of the uterus and pathology is helpful when transvaginal sonography fails to differentiate between the above pregnancies.

The estimated recurrence risk of EP ranges from 10%-27%, a 5 to 10 fold increase over the risk in general population. The main risk factor for EP is fallopian tube damage. Patients with a previous history of pelvic infection, especially those who underwent a conservative operation or tubal microsurgery for a tubal pregnancy, have a higher incidence of EP after assisted pregnancy. No separate study has been done to evaluate the factors predisposing to the risk for stump ectopic but it has been found that ipsilateral salpingectomy is a risk factor unique to interstitial pregnancy. Simpson et al. found 46 cases of interstitial pregnancy after ipsilateral salpingectomy with or without cornual resection.

Various theories have been postulated for the mechanism of recurrent ipsilateral ectopic pregnancy. Reported hypotheses include transperitoneal migration of spermatozoa or embryo through the patent tube to the side of the damaged tube. Another hypothesis is that the oocyte from the normal ovary may be fertilized normally in the patent tube and then later implant in the stump via intrauterine migration. It is also possible that despite the surgical excision of the tube following salpingectomy there is some degree of patency in the remaining interstitial part. Recanalization of isthmic stump allows for fertilization and implantation within this portion of the remnant tube. In patients undergoing ART, the chances of an embryo spontaneously implanting at the interstitial tubal segment are higher when compared to a spontaneous pregnancy. In addition factors related to embryo transfer procedure like volume of culture media with embryos, force used while embryo deposition, distance of embryo deposition from the fundus influence the chance of having an ectopic following IVF –ET. A review of the literature conducted by Chin et al. reported 22 cases of cornual pregnancies after IVF-ET.

Management of ectopic pregnancy can be either expectant or medical management with methotrexate in selected group of patients who fulfil the criteria or surgery (RCOG Greentop Guidelines). However, laparoscopic salpingectomy or salpingostomy is the preferred approach today (Grade B recommendation RCOG). Salpingectomy is preferable to salpingostomy if contralateral tube is healthy, as it is associated with lower rates of persistent trophoblastic tissue and subsequent recurrence while having the same intrauterine pregnancy rates. Concerning interstitial or cornual pregnancies, though pharmacological approach using methotrexate has been shown to be effective, there is yet insufficient evidence to recommend local or systemic approach. Moreover, RCOG guidelines have confirmed surgery as the mainstay in the management of cornual pregnancy with either conservative, laparoscopic or open surgical methods, and it reported medical therapy with methotrexate and potassium chloride injection as an option prior to laparoscopic horn excision. Nevertheless, an international consensus on the management of cornual or stump pregnancy is still awaited, as all the evidence reported in the guidelines come from non-analytical studies, such as case reports or are based on expert opinion.

Conclusion

IVF-ET is frequently proposed to treat tubal factor infertility. Unfortunately, IVF-ET may constitute a risk factor for Tubal Ectopic Pregnancy, as 2-5% of pregnancies from assisted reproductive technologies (ART) are ectopic in location. Infertile patients, who had a treated Tubal Ectopic Pregnancy before an IVF-ET treatment, may therefore be concerned about their subsequent pregnancy outcomes including increase in likelihood of recurrent Tubal Ectopic Pregnancy. Appropriate counseling of the couple regarding future recurrence risk of ectopic pregnancy, high index of clinical suspicion, initiating early and frequent monitoring following IVF-ET and prompt intervention will help in effective management aiming towards a successful outcome.

Faith, Hope and Perseverance are Key in the Walk of Life: A Case Report

milann
The Fertility Specialists

DR. ANU SADASHIV
Consultant, Reproductive Medicine
Milann, Kumara Park, Bangalore

DR. SOPHIYA MATHEWS
Jr Consultant, Reproductive Medicine
Milann, Kumara Park, Bangalore

Introduction

Evidence of an intrauterine pregnancy (IUP) with visualization of a gestational sac by transvaginal ultrasound (TVUS) is expected by 5 weeks gestational age at the earliest, or more than the "discriminatory zone", traditionally described as a β-hCG concentration of 1,500–2,000 IU/mL. β-hCG increase of less than 53% or a decrease of less than 12%–32% (depending on initial β-hCG level) in 2 days is concerning for ectopic pregnancy. A patient found to have a negative TVUS with serum β-hCG more than the discriminatory zone or a gestational age by last menstrual period of more than 5 weeks, is described as having a pregnancy of unknown location (PUL). Majority of PUL will either have a final outcome of an IUP (intrauterine pregnancy 17-41%), Failed IUP (47-70%) and ectopic pregnancy (8-16%). Studies have not, however, specifically examined outcomes of PUL resulting from IVF, which confers a higher baseline risk of EP (2%) more than the general population (1%)

Case report

Mrs X, 36-year-old, married for 8 years, diagnosed with primary infertility, POR (POSEIDON 3) underwent embryo pooling. 1st IVF cycle with PPOS protocol to get 2 oocytes, 1 M2 and 1 embryo arrested on day2. She underwent 2nd IVF cycle (PPOS) followed by fresh transfer of 2-8CGA and standard luteal phase support was prescribed. Her Beta HCG reports 2 weeks later showed suboptimal rise (Figure 1). She had no complaints and remained hemodynamically stable. In view of suboptimal beta HCG rise with scan showing no evidence of intra or extra-uterine pregnancy, she was diagnosed as Pregnancy of Unknown Location (PUL).

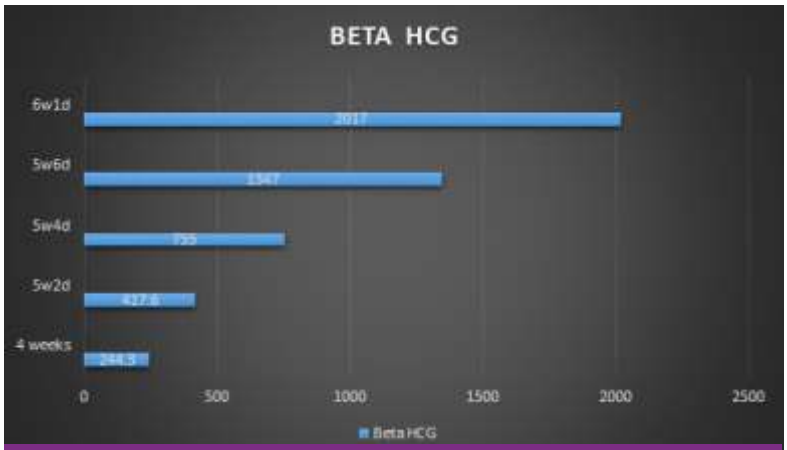

Figure 1 – Beta HCG reports

As her case fit the criteria for medical management (i) rising but plateauing serum Beta HCG titers; (ii) no intrauterine pregnancy on transvaginal ultrasound; (iii) patient being asymptomatic and hemodynamically stable; (iv) normal liver and renal function tests; (v) patient's consent and (vi) no known allergy to MTX. She was given a single intramuscular dose of MTX 50 mg/m2 on Day 1 after confirmation of normal baseline hematologic, hepatic, and renal function. Beta-HCG levels evaluated on Day4 and 7, showed a decline >15%. Weekly Beta HCG was repeated till negative Beta HCG report.

She underwent 3rd pooling cycle with mild stimulation protocol. Got 1 oocyte, 1 M2 and underwent fresh embryo transfer of 1-12CGA. Currently she is 35+ weeks pregnant. Her antenatal period has been uneventful till date.

| Discussion

Pregnancy of unknown location is a transient state in the diagnostic process, leading to a final diagnosis of viable or nonviable intrauterine pregnancy, ectopic pregnancy, or persistent pregnancy of unknown location. Studies have demonstrated that a Beta HCG rise of less than 53% or a decrease of less than 12-32% in 2 days is concerning of ectopic pregnancy. The treatment modalities depends on multiple factors like clinical condition of patient, HCG levels and TVUS findings. The Royal College Of Obstetricians and Gynecologists guidelines advise for an active intervention if HCG levels rise above 1000 IU/L or if levels plateau in women with PUL with minimum or no symptoms, but the type of intervention is not specified. The American College Of Obstetricians and Gynecologists advise on medical treatment with MTX for women with a confirmed or high clinical suspicion of ectopic pregnancy who are hemodynamically stable. Different modalities of treatment are as follows-

Expectant Management

In a patient who is asymptomatic, hemodynamically stable and Beta HCG declines >15% every 48 hours. This indicates a failing intrauterine pregnancy. Weekly Beta HCG is repeated till undetectable.

Medical Management

MTX has been used in PUL cases who are clinically stable and presumed to have ectopic pregnancy. This drug is a chemotherapeutic agent antagonist of folic acid and shows a high success rate. A dose of 50-mg/m MTX is injected intramuscularly, and if HCG does not decrease by at least 15% between days 4 and 7, then the same dose of MTX can be repeated. the patient should wait at least 3 months before trying to become pregnant after MTX treatment.

Medical Management

MTX has been used in PUL cases who are clinically stable and presumed to have ectopic pregnancy. This drug is a chemotherapeutic agent antagonist of folic acid and shows a high success rate. A dose of 50-mg/m MTX is injected intramuscularly, and if HCG does not decrease by at least 15% between days 4 and 7, then the same dose of MTX can be repeated. the patient should wait at least 3 months before trying to become pregnant after MTX treatment.

Surgical Management

A lack of visualization of the intrauterine gestational sac on TVUS, together with HCG values above the discriminatory zone, was considered an indication for laparoscopy. Currently, laparoscopy is reserved for cases of PUL with the symptoms or signs of hemoperitoneum. Whenever hemodynamic instability or clinical signs of rupture (increasing abdominal pain with falling hemoglobin levels, signs of intra-abdominal haemorrhage on TVUS) occurred, surgical intervention needs to be carried out.

In our case as patient was hemodynamically stable, medical management was preferred.

Insogna et al., described an alternative to methotrexate in PUL. These patients underwent outpatient endometrial sampling with Karman cannula aspiration. Patients with a beta-human chorionic gonadotropin decline ≥15% within 24 hours of sampling and/or villi detected on pathologic analysis were diagnosed with failing intrauterine pregnancy and had weekly beta-human chorionic gonadotropin measurements thereafter. Those patients with beta-human chorionic gonadotropin declines <15% and no villi identified were diagnosed with ectopic pregnancy and treated with intramuscular methotrexate (50 mg/m2) or laparoscopy.

| Conclusion

Women with PUL should be followed up until a final diagnosis is established. In addition to TVUS, it is recommended to keep a constant watch on the Beta HCG levels and patient condition. Fortunately, most cases are low risk and can be monitored by expectant management. However, the possibility of an ectopic pregnancy, which has high morbidity and mortality rates during the first trimester of pregnancy, remains.

This woman believed in the clinician, continued to come back for treatment after each failure and never failed to dream of having a child. She is an inspiration to the clinician and other patients.

Successful Management of Cervical Ectopic Pregnancy - A Case Report

milann
The Fertility Specialists

DR. NIKITHA PV
Jr. Consultant, Reproductive Medicine
Milann, J.P Nagar, Bangalore

DR. SUNITHA MAHESH
Medical Director, Milann Fertility
Milann, J.P Nagar, Bangalore
Milann, HSR Layout, Bangalore

Abstract

Cervical pregnancy is an extremely rare condition with potential grave consequences if not diagnosed and treated early enough. We present a case report of an early cervical ectopic pregnancy with a history of one previous caesarean section who was successfully managed with uterine artery embolization and Dilatation and Evacuation.

Introduction

Cervical ectopic pregnancies account for less than 1% of all ectopic pregnancies, with an estimated incidence of one in 2500 to one in 50,000. In the past, cervical pregnancy was associated with significant haemorrhage and was treated presumptively with hysterectomy. Improved ultrasound resolution and earlier detection of these pregnancies has led to the development of more conservative treatments that attempt to limit morbidity and preserve fertility. There are reports of association with chromosomal abnormalities as well as a prior history of procedures that damage the endometrial lining such as caesarean section, intrauterine device, and in vitro fertilization.

Case Report

A 33 Year old woman, gravida 2 para 1 live 1 abortion 2 with 1 previous LSCS, presented to our department with 2 months of amenorrhoea with urine pregnancy test positive. Her menstrual cycles were irregular 4-5 days/25- 45 days. Her medical history was unremarkable, with previous history of suction and evacuation for missed abortion 9 years ago and lower segment caesarean section 7 years ago. No history of pain abdomen, bleeding per vagina, no previous history of pelvic inflammatory disease. Vital signs were stable, and the abdomen was soft and not tender.

On transvaginal scan, uterine cavity appeared empty with endometrial thickness of 15mm. (See Fig1) Endo cervical region showed a well defined gestational sac with good decidual activity Good vascularity noted around the sac. Sac contour regular. No perisac fluid collection. Yolk sac and fetal pole with CRL of 0.35 cms (6 weeks) with good cardiac activity of 112 /min. Distal cervical length from the sac to the external os measured approximately 9.8 mm. Cervical length – 3.15 cms. External os was closed. Both ovaries normal

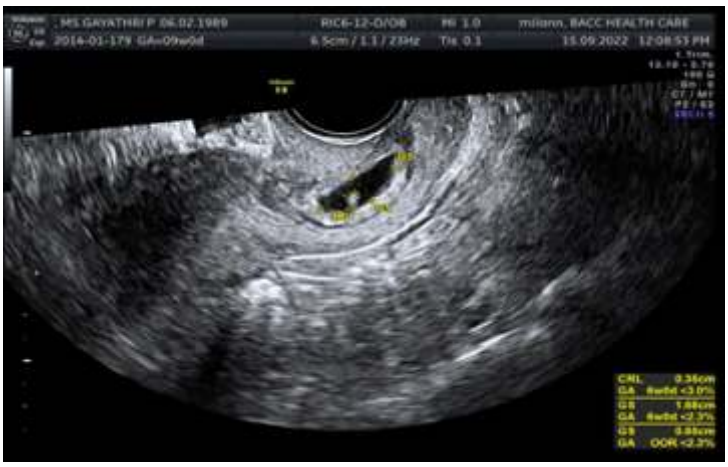

Fig1. Ultrasound scan findings of closed internal cervical os and an empty uterine cavity.

Impression- Cervical Ectopic Pregnancy.

Beta HCG done on 15/09/22- 8168 mIU/ml.

Management

Patient was given Tab.Mifepristone 200 mg and was posted for high risk uterine artery embolization and D and E.

Under LA, using 5F uterine artery catheter and microcatheter, B/L uterine arteries catheterisation done and embolized with 500micron PVA particles (See Fig 2). Catheter and sheath removed and Dilatation and Evacuation done with minimal blood loss. Haemostasis achieved. Tab Misoprostol 400 mcg P/R. Tissue sent for HPE

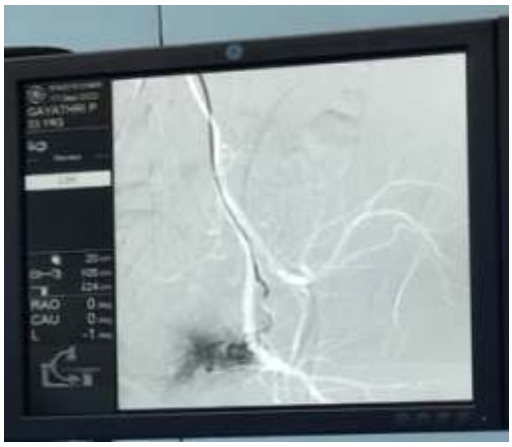

Fig 2: Fluoroscopic image of uterine artery embolization showing vascularity in the uterine vessels

Beta HCG repeated after 48 hrs after evacuation – 402 mIU/ml.

Beta HCG repeated after 10days after evacuation – 78mIU/ml.

HPE of products of conception – section reveal fragments of decidua and villi.

Discussion

Although cervical pregnancy is a rare form of ectopic pregnancy it is a life-threatening disease due to its late diagnosis in asymptomatic women. A variety of conditions are thought to predispose to the development of a cervical pregnancy, including previous therapeutic abortion, previous surgical termination of pregnancy, endometrial ablation, Ashermann syndrome, diethyl stilbestrol exposure, leiomyomas, previous caesarean section or other cervical or uterine surgery and assisted reproductive techniques. In our case, a previous caesarean delivery was the only known risk factor.

The Diagnostic Criteria for cervical pregnancy were established based on histologic analysis of a hysterectomy specimen. Clinical criteria include the following findings

- The uterus is smaller than the surrounding distended cervix
- The internal os is not dilated.
- Curettage of the endometrial cavity is non productive of placental tissue.
- The external os opens earlier than in spontaneous abortion.

The Ultrasound Criteria for cervical pregnancy (Rubins Criteria)

- Echo free uterine cavity or the presence of a false gestational sac only
- Decidual transformation of the endometrium with dense echo structure
- Diffuse uterine wall structure
- Hourglass uterine shape
- Ballooned cervical canal
- Gestational sac in the endocervix
- Placental tissue in the cervical canal
- Closed internal os.

Recognizing its sonographic appearance is the first step for correct management, because it may be mistaken for an intrauterine pregnancy, an incomplete abortion or even an endocervical cyst. Transvaginal ultrasound seems to be the most appropriate imaging method. MRI of the pelvis has also been used in the situation.

Treatment choices include surgical and non surgical treatment. Non surgical treatment including intra-amniotic and systemic methotrexate administration. The diagnosis may not be suspected until the patient is undergoing suction curettage for a presumed incomplete abortion and hemorrhage occurs. In some cases bleeding is light, where as in others, there is hemorrhage. Various techniques that can be used to control bleeding include uterine packing, lateral cervical suture placement to ligate the lateral cervical vessels, placement of cerclage, and insertion of an intracervical balloon tamponade, reduction of blood supply by angiographic artery embolization can be used. If laparotomy is required , an attempt can be made to ligate the uterine and internal iliac arteries. When none of these methods is successful, hysterectomy is required. In most reported cases of cervical pregnancy, treatments from more than one category are used

Conclusion

Although cervical pregnancy is rare, increased number of cases are being reported because of risk factors like high cesarean section rate and increased assisted reproductive techniques for management of infertility. The success of conservative treatment depends on the timely and prompt diagnosis by early ultrasound, which can reduce the chances of severe life threatening hemorrhage necessitating hysterectomy or blood transfusion and improved the possibility of ongoing fertility in affected patients.

Higher Order Pregnancies - Good News or Bad?

milann
The Fertility Specialists

DR. ANUSHA GP
Consultant, Reproductive Medicine
Milann, Kumara Park, Bangalore

DR. SHRADDHA POL
Jr Consultant, Reproductive Medicine (former)
Milann, Kumara Park, Bangalore

Introduction

The widespread use of assisted reproductive technology has raised a question about the safety for new born and mothers. An increased frequency of preterm delivery, low birth weight, high caesarean section rate, risk of haemorrhage and pregnancy-induced hypertension, high proportion of multiple pregnancies after assisted reproduction technologies has increased the rate of obstetric and perinatal complications.

Case Report

Mrs X, 31 years old, primary infertility with male factor infertility (azoospermia) with previous cancelled IVF cycle with poor ovarian response underwent 3 attempts of Intra Uterine Insemination (IUI) with donor sperm (AID) at Milann Hospital. She had a missed abortion in the 1st AID cycle which was medically managed. In view of failed IUI cycles & POR with AMH of 1.4 she was counselled for IVF with donor sperm. Due to poor ovarian response (only 2 dominant follicles of 18mm), decision was made to cancel IVF and convert to an IUI cycle. She had quadruplet conception from the same. Decision to reduce quadruplet into twin gestation was made. However, patient had per vaginal bleeding and fever at 13 weeks of gestation. Hence reduction was scheduled at 15 weeks of gestation. Post reduction pregnancy went uneventful with a normal Level II scan. She developed preterm labor at 29 weeks of gestation due to the infection cause by reduced twin. She expelled the reduced conceptus in the lower segment near cervix at 29 weeks which formed a nidus for ascending infection. Due to abnormal lie of both the twins, she was taken up for Emergency LSCS. She delivered a male child of 900grams and a female Child of 1120grams both managed at NICU for 15 days. After having been through the physical, mental and the financial turmoil, the family of 4 was completed. Currently babies are 7months and healthy.

Discussion

The incidence of multifetal gestations has risen dramatically over the past few decades. Assisted reproductive techniques (ARTs) and the rising trend in advanced maternal age at first birth are the principal factors involved. This implicates an increasing need for specialised tertiary referral fetal medicine units to address the increasing workload generated with twins and multifetal pregnancies. This includes the accurate assignment of chorionicity, prenatal screening, fetal reduction and optimal antenatal surveillance aimed at reducing the associated perinatal disease burden, which extends to include the availability of experts in fetal intervention techniques.

Multiple pregnancy leads to a strong increase in obstetric complications, perinatal morbidity, maternal and child mortality rate, congenital malformations, pre-term birth, and long-term social, psychological and financial difficulties.

The risks for stillbirth and perinatal mortality in twins and perinatal death in triplets are approximately five, seven and nine times those of singleton pregnancies, respectively. This is largely attributable to the increased rate of spontaneous and iatrogenic preterm delivery, in which multifetal gestations are 13 times more likely to deliver less than 32 weeks' gestation compared with singleton pregnancies. The increased rate of preterm delivery confers a risk for developing cerebral palsy to be four times that of singletons. Withstanding the short and long-term complications of prematurity, multiple pregnancy is associated with increased risk for congenital anomalies, disorders of fetal growth and twin–twin transfusion syndrome (TTTS), in addition to the increased maternal complications of preeclampsia, gestational diabetes, antepartum haemorrhage and the requirement for caesarean delivery. By applying a strategy of close antenatal surveillance and delivery at 36 to 37 weeks' gestation for uncomplicated monochorionic (MC) twins, extending this to 38 weeks' gestation for dichorionic (DC) twins, it has been suggested that perinatal morbidity can be minimised significantly, albeit with a residual risk for 1.5% of late IUFD in MC twins. The goal of antenatal surveillance and optimum timing of delivery in multiple pregnancies is thus aimed at reducing the risk for in utero demise, balanced against minimising perinatal morbidity from prematurity.

Measures to prevent multiple pregnancies in an IUI cycle can be divided into primary and secondary measures. Primary measures include attempting to prevent the growth of more than two to three dominant follicles. According to a systematic review and meta-analysis including 14 studies multifollicular growth resulted in significantly higher pregnancy rates compared to monofollicular growth (15 versus 8.4%). Compared with one dominant follicle, pregnancy rates increased by a further 5, 8 and 8%, respectively, when two, three or four dominant follicles were present. Subsequently, the risk of multiple pregnancies after two, three and four dominant follicles increased, at 6, 14 and 10%, respectively. Another primary measure to prevent multiple pregnancies is to apply the appropriate drug and doses, and to individualize the doses whenever possible.

Cycles should be closely monitored by regular vaginal ultrasounds and when more than two to three follicles larger than 15 mm, or when more than five follicles larger than 10 mm are seen, secondary measures can be advocated like cycles can be cancelled and heterosexual couples should be advised to abstain from unprotected intercourse. Conversion to IVF might be additional options for reducing the risk of multiple pregnancy. However, multifetal reduction should be prevented at all costs with the above-mentioned measures for prevention of multiple pregnancies with IUI.

Measures to prevent multiple pregnancy in IVF treatment would be an overall change in transfer policy to transfer only one embryo at a time would certainly result in mainly singletons. This might be unacceptable to both patients and practitioners, who aim at the best possible rates of success. An alternative to an overall one embryo transfer would be an individualized embryo transfer policy.

In our case converting an IVF cycle into an IUI cycle for a suboptimal response with only 2DF subjected the patient into a higher order gestation. Performing fetal reduction to reduce the incidence of preterm delivery was of minimal help. The reduced twins posed a nidus of infection for the developing twin gestation.

Conclusion

Given the current "Epidemic of multiple pregnancies" in today's western world, it is surprising that most research has failed to examine the perinatal health in parents of multiples.

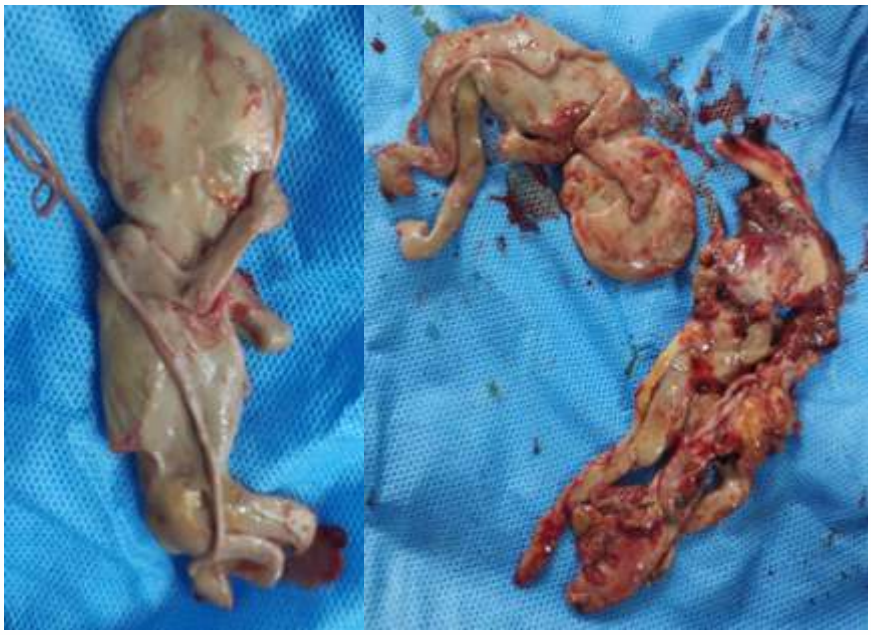

Product of Reduced Conceptus

Acknowledgements: We acknowledge our entire team of experts who were involved in the management of this case - Dr. Shilpa Reddy, Dr. Varini Murthy, Pediatrics team and the nursing team of Milann.

MILANN ACADEMICS

Fellowship Programmes

National Board of Examinations

Post-Doctoral Fellowship Programme in Reproductive Medicine

Duration: 2 Years

Number of Seats : 4 Per Year

Eligibility Criteria: MD/MS/DNB

Selection: National Eligibility cum Entrance Test (NEET) details of which are posted on the NBE website.

Web: www.natboard.nic.in

Rajiv Gandhi University of Health Sciences

Post-Doctoral Fellowship Programme in Reproductive Medicine

Duration: 18 Months

Number of Seats : 4 every year (Courses start in September every year)

Eligibility Criteria: MD/MS/DNB or DGO (with 3 years experience)

Selection: Based on a written exam (MCQ) followed by Interviews.

Web: www.rguhs.ac.in

BACC Healthcare Institutional Fellowships

Post-Doctoral Fellowship Programme in Reproductive Medicine

Duration: 1 Year

Number of Seats : 6 Per Year

Eligibility Criteria: MD/MS/DNB or DGO (with 3 years experience)

Selection: Based on a written exam (MCQ) followed by Interviews

Web: www.milann.co.in

Fellowship in Clinical Embryology

Duration: 1 Year

Number of Seats : 4 Per Year (Bangalore, Delhi & Chandigarh)

Eligibility Criteria: MSc (Life Sciences) / MBBS / MD (OBG & Anatomy)

Web: www.milann.co.in

PhD Programmes

PhD Programme in Reproductive Biology (in association with)

Rajiv Gandhi University of Health Sciences

Vellore Institute of Technology

NITTE University

MSc Embryology

MSc in Clinical Embryology (In association with JSS University, Mysore)

Course Duration: 2 years

Eligibility: BSc (Biotechnology) or BSc with at least one subject of Biological Sciences

No of Seats: 10 per year

Web: https://www.jssuni.edu.in

SHORT TERM TRAINING COURSES

Course	Duration
Basic Infertility Course	1 Week
Advanced ART Course for Clinicians	3 Weeks
Advanced ART Course for Embryologists	3 Weeks
Andrology Course	1 Week
ICSI (Micromanipulation)	10 Days
Certificate Course for Clinicians	3 Months
Certificate Course for Embryologists	3 Months
Training Course in Gynae Endoscopy	1 Month
Simulator Based Training in Basic 2D Obstetric Ultrasound	2 Days
PGT Course (Pre-Implantation Genetic Testing)	3 Days

academics@milann.co.in www.milann.co.in/academics

BACC Healthcare Pvt Ltd, No7, East Park Road, Kumara Park East, Bangalore

+91 7829192444 | +91 80-2243392 | 22011311

milann The Fertility Specialists A HCG adding life to years Company